

## Spontaneous Cure after Natural Infection with *Gnathostoma turgidum* (Nematoda) in Virginia Opossums (*Didelphis virginiana*)

Hilario Torres-Montoya,<sup>1</sup> Xochilth Galaviz-Renteria,<sup>1</sup> Hipólito Castillo-Ureta,<sup>1</sup> Hector Lopez-Moreno,<sup>2</sup> Yukifumi Nawa,<sup>3</sup> Angel Bojorquez-Contreras,<sup>2</sup> Sergio Sanchez-Gonzalez,<sup>1</sup> Sylvia Díaz-Camacho,<sup>2,5</sup> Rodrigo Rocha-Tirado,<sup>4</sup> and Jose Rendon-Maldonado<sup>2,5</sup> <sup>1</sup>Escuela de Biología, Universidad Autónoma de Sinaloa, Av. de las Américas y Blvd. Universitarios S/N, Culiacán, Sinaloa 80010, México; <sup>2</sup>Facultad de Ciencias Químico Biológicas, Universidad Autónoma de Sinaloa, Av. de las Américas y Blvd. Universitarios S/N, Culiacán, Sinaloa 80010, México; <sup>3</sup>Faculty of Medicine, Khon Kaen University, 123 Mitraparp Highway, Maung, Khon Kaen, 40002, Thailand; <sup>4</sup>Facultad de Medicina Veterinaria y Zootecnia, Universidad Autónoma de Sinaloa, Carretera Internacional Km 3.5 sur S/N, PO Box 1057, Culiacán, Sinaloa, México; <sup>5</sup>Corresponding author (email: jgrendonm@uas.edu.mx)

**ABSTRACT:** Seasonality of the nematode *Gnathostoma turgidum* in Virginia opossums (*Didelphis virginiana*) in the wild has been reported; however, the mechanisms involved in deworming are unknown. We monitored the parasitologic and biologic changes in four Virginia opossums naturally infected with *G. turgidum* by coproparasitologic examination and abdominal ultrasonography. Eggs became detectable in the feces of opossums in May, peaked in July and August, and suddenly decreased in October. Adults of *G. turgidum* were expelled in the feces mainly in September. Ultrasonography of the liver showed slight damage during May. Lesions in the stomach appeared in April and persisted until September. The abnormalities of the liver and stomach were resolved in November. These data suggest that *G. turgidum* is likely expelled as a result of host immunologic mechanisms, although termination of a natural life span cannot be definitively excluded.

**Key words:** *Didelphis virginiana*, expulsion, *Gnathostoma turgidum*, nematode, spontaneous cure.

*Gnathostoma turgidum* Stossich, 1902, is a gastric nematode that occurs in several species of opossums, including the Virginia opossum (*Didelphis virginiana*) in several countries of the Americas (Johnson 1970). In Mexico, *G. turgidum* is present in several states, including Guerrero, Chiapas, and Oaxaca (Lamothe-Argumedo et al. 1998). Recently, Tecualilla, in the municipality of Escuinapa, Sinaloa State, Mexico, was shown to be an enzootic area of *G. turgidum*, with a prevalence of more than 50% in opossums (Díaz-Camacho et al. 2009). During a >1-yr longitudinal survey in this area, pronounced seasonal changes of infection were observed in

opossums. These changes included synchronized maturation of larvae to young adults in the liver, with subsequent relocation to the stomach to become mature adults (Nawa et al. 2009). All opossums captured from October to December were uninfected with *G. turgidum*.

We investigated whether “spontaneous cure” of *G. turgidum* in *D. virginiana* is a component of the parasite-host interaction. Naturally infected opossums were captured and chronologic changes in *G. turgidum* infection were monitored by coproparasitologic examination and ultrasonography of the liver and stomach.

With permission from the Mexican Wildlife Animal authorities (Dirección General de Vida Silvestre, SEMARNAT, 02197/12), we captured four opossums in February 2011 using hunting nets and night lights near the small water reservoirs of Ojo de Agua and Tanque Via, in Tecualilla, Escuinapa, Sinaloa, Mexico (22°45'28"N, 105°40'25"W). The captured animals were marked (1T–4T), and their sex, body weight, and other morphometric data recorded. A male opossum captured in a nonenzootic area in the municipality of Navolato, Sinaloa, Mexico (24°45'55"N, 107°42'7"W) was used as a negative control (5T). In addition, one opossum killed by local hunters in the same enzootic area described above in March 2013 was packed in ice, transported to our laboratory, and examined within 48 hr of being killed. This opossum was used for confirmation of the ultrasonographic

imaging and actual visceral lesions. After ultrasonographic imaging examination, the thoracic and abdominal viscera were examined visually for nematodes.

Live animals were transported to the laboratory and kept under natural temperature, humidity, and light conditions, with no access to external food sources. They were housed individually in 50×50-cm wire-mesh cages fitted with a catch pan for fecal collection and fed commercial dog food and water ad libitum. Catch pans were cleaned daily and fecal samples from each opossum were collected weekly. The presence of parasite eggs in stools was determined by flotation (Faust) and sedimentation (Ritchie) techniques (Beaver et al. 2003). For quantification of *G. turgidum* eggs, a McMaster chamber counting slide (Chalex Corp., Wallowa, Oregon, USA) was used following the manufacturer's instructions. Additionally, whole stools were visually examined daily before cleaning the catch pan to search for adult nematodes or fragments thereof.

Adult worms from opossum feces were measured using an electronic vernier caliper (Mitutoyo, Kawasaki, Kanagawa, Japan) and examined under a light microscope (Primo Star, Zeiss, Göttingen, Germany) to record the number of rows of hooklets on the cephalic bulb, proportion of the body covered with spines, and shape and height of the spines (Díaz-Camacho et al. 2009). The morphologic identification of adult *G. turgidum* was performed according to Bertoni-Ruiz et al. (2011).

The presence or absence of possible *Gnathostoma*-associated lesions was corroborated by abdominal ultrasonography (stomach and liver) using a veterinary digital diagnostic ultrasound system, DP-2200VET (Mindray, Mahwah, New Jersey, USA). The opossums were sedated using a 10 mg/kg intramuscular injection of tiletamine/zolazepam (Zoletil50, Virbac, Guadalajara, Jalisco, Mexico). Hyperechoic images suggestive of pathologic changes in the liver and gastric wall were recorded.

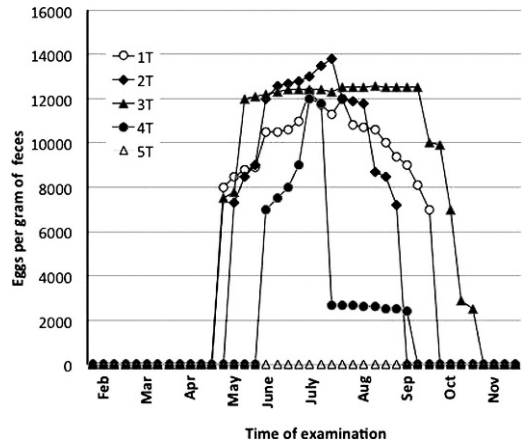


FIGURE 1. Kinetic changes of *Gnathostoma* eggs detection in feces of four naturally infected Virginia opossums (*Didelphis virginiana*) from Sinaloa State, Mexico, 2011.

All captured animals weighed 1.1–1.3 kg at the beginning of the study. They exhibited unusual hair loss and a soft dirty coat. Naturally infected opossums generally gained approximately 800 g after spontaneous worm expulsion in December.

The results of weekly fecal egg examination are shown in Figure 1. Feces of all animals were negative for *Gnathostoma* spp. eggs from February to April, but other nematode eggs such as *Turgida turgida* and *Strongyloides* spp. were present. In the four naturally infected opossums, *Gnathostoma* eggs became detectable in May, rapidly rose to a peak around June, remained at a high level until September/October, and decreased sharply thereafter. No *Gnathostoma* sp. eggs were detected in feces of the negative control.

Abdominal ultrasonography revealed hepatic and gastric hyperechoic areas in all infected opossums (Fig. 2). In the liver, areas suggestive of damage were scattered in the parenchyma in various lobes from March (Fig. 2A) until August, but thereafter complete regeneration was observed in all infected animals. In the opossum killed by hunters in March 2013, visual examination revealed larvae and one immature adult *G. turgidum* in the liver

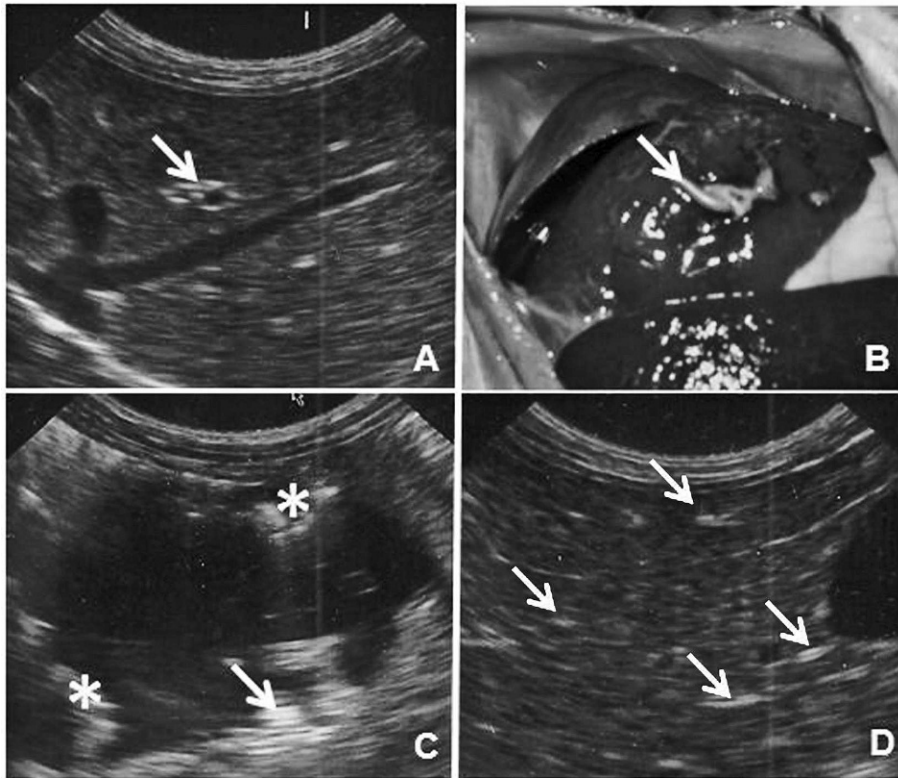


FIGURE 2. Ultrasound images of the liver (A, D) and stomach (C), and gross image (B) of *Gnathostoma turgidum*-infected Virginia opossums (*Didelphis virginiana*) from Sinaloa, Mexico, 2011. (A) The arrow shows a heterogeneous and hyperechoic area. (B) An apparent larval *G. turgidum* (arrow) in the liver of a hunter-killed opossum examined in March. (C) Irregular thickening of the gastric mucosa (asterisk) and foreign body mobility (arrow). (D) Healing areas (arrows) of regenerated liver. A, C, and D are the same opossum examined in March, July, and November 2011, respectively.

(Fig. 2B). No nematodes were found in the stomach. Stomach ultrasonography of infected opossums revealed foreign bodies with apparent mobility, especially in July (Fig. 2C) and was consistent with the presence of eggs in the feces.

All naturally infected opossums gained weight during November and showed a marked improvement in the quality of hair after recovery of the hepatogastric lesions. The control opossum had bright, healthy, abundant hair, homogeneous liver parenchyma, and a healthy stomach throughout the study.

Twelve worms were expelled from the four *Gnathostoma* egg-positive opossums between the first week of May and mid-October, with the peak recovery during

September (Table 1). Length of female worms ranged from 88 mm to 99 mm (mean 92.3 mm,  $n=3$ ); males were 44 mm to 79 mm (mean 60.5 mm,  $n=6$ ). The cephalic bulb in all adults was armed with uncinete conical base hooklets in eight transverse complete and two incomplete rows, and the posterior third of the body lacked cuticular spines.

Synchronized migration, beginning with the appearance of immature adults in the liver in early February, followed by their growth in the liver, relocation to the stomach, development to mature adults, and final disappearance in September has been documented (Nawa et al. 2009). In our study, captured opossums were infected with *G. turgidum* before they were

TABLE 1. Morphometric data of adult *Gnathostoma turgidum* recovered from feces of Virginia opossums (*Didelphis virginiana*) from an enzootic area for gnathostomiasis, Sinaloa State, Mexico, 2011.<sup>a</sup>

Opossum ID	Number expelled	Date expelled	Body length (mm)	Sex	No. of rows of hooklets	Body spines coverage (%)
1T	3	24 May	63	M	10	53
		11 September	ND	F	ND	ND
		21 September	57	M	ND	47.3
2T	3	29 August	88	F	10	35.7
		10 September	99	F	ND	52.5
		11 September	44	M	10	56
3T	5	26 June	51	M	10	54.9
		6 August	73	M	10	53.9
		26 September	79	M	10	35.4
		24 October	90	F	ND	ND
		24 October	57	ND	ND	ND
4T	1	24 October	ND	ND	ND	ND
5T	0	NA	NA	NA	NA	NA
Total	12					

<sup>a</sup> ND = not determined; NA = not applicable; M = male; F = female.

caught in February, possibly by eating a frog or turtle infected with infective third-stage larvae, as previously suggested (Mosqueda Cabrera et al. 2009). *Gnathostoma* eggs appeared in the feces almost synchronously in early May. From June to August, persistent high counts of eggs per gram were observed. From August to October, live and dead adults were expelled. These results are in accordance with our previous observations of the seasonality of *G. turgidum* using a longitudinal survey of wild opossums in the same area (Nawa et al. 2009).

It appears that the seasonality of *G. turgidum* infection in opossums is a result of a host-parasite interaction. Similar seasonality occurs with *Gnathostoma procyonis* in raccoons, (*Procyon lotor*; Lockhart 2007). Although persistent infection in the definitive host was reported for *Gnathostoma spinigerum* (Miyazaki 1960), a slight seasonal fluctuation was observed in experimentally infected dogs (Maleewong et al. 1992). The sudden termination of *G. turgidum* infection in the opossums in our study is unlikely to reflect the lifespan of the parasite because the majority of expelled adults were still alive and the females were laying eggs. Thus, the host immune system may have achieved immune-mediated

deworming. Many examples of expulsion in natural and experimental infections have been reported for intestinal nematodes (Else and Finkelman 1998). In particular, the importance of heparin-binding proteins (Maruyama et al. 2000) and proteoglycans produced by intestinal goblet cells and mast cells (Nawa et al. 1994) has been demonstrated. Our results show that after a period of egg production, the adult nematodes were expelled in the feces, and the hepatic and gastric lesions healed. Confirmatory experiments regarding the involvement of the immune system in the seasonality of *G. turgidum* in opossums are currently underway in our laboratory.

This work was supported by institutional funds (PROFAPI-UAS2009/176, 2011/139, and 2012/145). E.H.T.M. was supported by CONACYT scholarship 103950. We thank Mónica González-Lázaro for reviewing the use of English in the manuscript.

#### LITERATURE CITED

- Beaver PC, Jung RC, Cupp EW. 2003. Spirurida: Dracunculus y otros. In: *Parasitología clínica de Craig Faust*. 3rd Ed, Tay Zavala J, Gutiérrez Quiroz M, García Yañez Y, editors. Masson Doyma, Mexico, DF, Mexico, pp. 334–337.

- Bertoni-Ruiz F, Lamothe Argumedo MR, García-Prieto L, Osorio-Sarabia D, León-Régagnon V. 2011. Systematics of the genus *Gnathostoma* (Nematoda: Gnathostomatidae) in the Americas. *Rev Mex Biodivers* 82:453–464.
- Díaz-Camacho SP, Willms K, Rendon-Maldonado JG, de la Cruz-Otero MC, Delgado-Vargas F, Robert L, Antuna S, Leon-Regagnon V, Nawa Y. 2009. Discovery of an endemic area of *Gnathostoma turgidum* infection among opossums, *Didelphis virginiana*, in Mexico. *J Parasitol* 95:617–622.
- Else KJ, Finkelman FD. 1998. Intestinal nematode parasites, cytokines and effector mechanisms. *Int J Parasitol*, 28:1145–1148.
- Johnson SA. 1970. Biology of the raccoon. (*Procyon lotor varius*) Nelson and Goldman in Alabama. *Bulletin 402, Agricultural Experiment Station*. Auburn University, Auburn, Alabama, 148 pp.
- Lamothe-Argumedo R, Akahane H, Osorio SD, García PL. 1998. Hallazgo de *Gnathostoma turgidum* en *Didelphis virginiana* de Temascal, Oaxaca México; *Ann Inst Biol, UNAM. Serie Zoológica* 69:225–229.
- Lockhart JM. 2007. *Gnathostoma procyonis* from South Georgia and North Florida raccoons. *J Parasitol* 93:1533–1536.
- Maleewong W, Pariyanonda S, Sitthithaworn P, Dacaseegocw W, Pipitgool V, Tesana S, Wongkham C, Intapan P, Morakate N. 1992. Seasonal variation in the prevalence and intensity of canine *Gnathostoma spinigerum* infection in northeastern Thailand. *J Helminthol* 66:72–74.
- Maruyama H, Hatano H, Kumagai T, El-Malky M, Yoshida A, Ohta N. 2000. *Strongyloides venezuelensis*: Heparin-binding adhesion substances in immunologically damaged adult worms. *Exp Parasitol*, 95:170–175.
- Miyazaki I. 1960. On the genus *Gnathostoma* and human gnathostomiasis with special reference to Japan. *Exp Parasitol* 9:338–370.
- Mosqueda Cabrera MA, Sanchez Miranda E, Carranza Calderón L, Ortiz Nájera HE. 2009. Finding advanced third-stage larvae of *Gnathostoma turgidum* Stossich, 1902 in Mexico from natural and experimental host and contributions to the life cycle description. *Parasitol Res* 104:1219–1225.
- Nawa Y, Ishikawa N, Tsuchiya K, Horii Y, Abe T, Khan AI, Bing-Shi, Itoh H, Ide H, Uchiyama F. 1994. Selective effector mechanisms for the expulsion of intestinal helminthes. *Parasite Immunol* 16:333–338.
- Nawa Y, de la Cruz-Otero MC, Zazueta-Ramos M, Bojórquez-Contreras A, Sicairos-Felix J, Campista-León S, Torres-Montoya EH, Sanchez-Gonzalez S, Guzmán-Loreto R, Delgado-Vargas F, Díaz-Camacho SP. 2009. Is *Gnathostoma turgidum* an annual parasite of opossums? Drastic seasonal changes of infection in *Didelphis virginiana* in Mexico. *J Parasitol* 95:908–912.

Submitted for publication 20 March 2013.

Accepted 1 October 2013.