



ELSEVIER

Available online at www.sciencedirect.com

SCIENCE @ DIRECT®

Veterinary Parasitology 115 (2003) 321–327

veterinary
parasitology

www.elsevier.com/locate/vetpar

Short communication

Prevalence and tissue distribution of *Besnoitia darlingi* cysts in the Virginia opossum (*Didelphis virginiana*) in Michigan

Hany M. Elsheikha^a, Linda S. Mansfield^b,
Scott D. Fitzgerald^c, Mahdi A. Saeed^{a,*}

^a Molecular Epidemiology Laboratory, National Food Safety and Toxicology Center, College of Veterinary Medicine, Michigan State University, East Lansing, MI 48824, USA

^b Department of Microbiology and Molecular Genetics, Michigan State University, East Lansing, MI 48824, USA

^c Diagnostic Center for Population and Animal Health, Michigan State University, East Lansing, MI 48824, USA

Received 24 December 2002; received in revised form 7 May 2003; accepted 20 May 2003

Abstract

Specimens of Virginia opossums (*Didelphis virginiana*) in Michigan were examined over 1 year to document the presence of *Besnoitia darlingi* cysts. Cyst morphology, prevalence, seasonal variation, and tissue sites of isolation were studied. Histology and ultrastructural features of the detected cysts and bradyzoites were consistent with *B. darlingi*. In the opossums, *B. darlingi* had intracellular tissue cysts. Tissue cysts had a mean diameter of 560 μm and were separated from the host tissue by a thick (5–20 μm) cyst wall. Overall prevalence of *B. darlingi* cysts in opossums was 10.9% (15/137). Variations in the prevalence were detected during spring (3/17; 17.6%), summer (10/34; 29.4%), and fall (2/60; 3.3%). No cysts were detected in the specimens examined during winter (0/26; 0%). Numerous *B. darlingi* cysts were detected in ears, conjunctiva, tongue, abdominal muscles, diaphragm, stomach, heart, liver, kidney, lung, and spleen. Cysts were detected mainly in adult female opossums that were debilitated. Ear was the most frequent organ from which the cysts were reported (10/15; 66.7%) when compared individually with other body tissues ($P < 0.05$).

© 2003 Elsevier B.V. All rights reserved.

Keywords: *Besnoitia darlingi*; Cysts; Opossum; Prevalence

* Corresponding author. Tel.: +1-517-432-9517; fax: +1-517-432-2310.

E-mail address: saeeda@msu.edu (M.A. Saeed).

1. Introduction

Besnoitia darlingi is a cyst-forming heteroxenous coccidian parasite. It has a life cycle that requires intermediate and definitive hosts. The Virginia opossum (*Didelphis virginiana*) serves as an intermediate host and the domestic cats serve as a definitive host (Smith and Frenkel, 1977, 1984; Dubey et al., 2002). Opossums may become infected with *B. darlingi* orally by ingesting infected tissues containing cysts through cannibalism, by ingesting food or water contaminated with oocysts excreted by cats, or experimentally through intraperitoneal inoculation with tachyzoites (Smith and Frenkel, 1977).

B. darlingi has been recognized for over 80 years in certain Central American lizards and American opossums (Schneider, 1967; Smith and Frenkel, 1984). It is a common parasite of Virginia opossum (*D. virginiana*) in the United States (Dubey et al., 2002). *B. darlingi* cysts had been reported in one opossum from Texas (Stabler and Welch, 1961), 1 of 5 opossums from Lexington, Kentucky (Conti-Diaz et al., 1970), 8 of 13 examined from Boone County, Missouri and Illinois (Flatt et al., 1971), 2 of 5 opossums from the Kansas City area (Smith and Frenkel, 1977), and 4 of 6 opossums from Indiana (Jack et al., 1989). Recently, in Mississippi *B. darlingi* cysts from two infected opossums were used in biological experiments as a source of *Besnoitia* organisms for establishment of infection in intermediate and definitive hosts (Dubey et al., 2002). All these reports examined small numbers of opossums. In addition, seasonal variation of the incidence of *B. darlingi* infection has not been previously reported.

The objectives of the present study were to expand the numbers of animals observed, document microscopic and ultrastructure characteristics of *B. darlingi* cysts, investigate the prevalence, and effects of season, age, gender, and body condition on *B. darlingi* infection in Michigan opossums, and demonstrate the most frequent sites of *B. darlingi* cysts in opossum's tissues.

2. Materials and methods

Opossum carcasses ($n = 137$) used in this study were either from animals killed by automobiles on the roadways or live-trapped and humanely sacrificed. All opossums were collected from south central (Ingham county, [42°38'29"N to 42°31'21"N and 84°20'36"W to 84°34'28"W]) MI, USA during 2002. Freshly killed opossums (~1 day after death) were only examined and opossums carcasses that showed any signs of decomposition were excluded. Based on the state opossum census data, this was the area of highest opossum abundance. Each animal was assigned an identification number, and data concerning age, gender, body condition, and location of collection were gathered.

At necropsy, ears, skin, tongue, conjunctiva, and the visceral surfaces were examined for the presence of white cysts suggestive of *Besnoitia*. Also, histological sections from samples of liver, spleen, kidney, lung, heart, stomach, adrenal glands, ears, conjunctiva, abdominal muscles, tongue, and diaphragm were fixed in 10% neutral buffered formalin and stained with hematoxylin and eosin (H&E) for light microscopic examination. Cysts from liver were post fixed in 1% osmium in 0.1 M phosphate buffer for 3 h, dehydrated through graded alcohols, rinsed in propylene oxide, then transferred to resin: propylene

oxide mixtures of 50, 75%, and then 100% resin (approximately 12 h for each incubation). The resin was a mixture of Poly/Bed 812:Araldite:DDSA in the proportion 5:4:12. DMP-30 (Dimethylaminoethylphenol) was used as an accelerant, and the blocks were cured for 2 days at 60 °C. Thick sections (1 µm) were cut with glass knives and thin sections (50 nm) were cut with a diamond knife. Thick sections were stained with a mixture of 1% toluidine blue and 0.1% basic fuchsin. Thin sections were stained with uranyl acetate and lead citrate and examined with a Phillips 301 transmission electron microscope (TEM).

Opossum specimens were examined for *Besnoitia* cysts for 1 year with seasonal sampling (Winter: January–March, $n = 26$; Spring: April–June, $n = 17$; Summer: July–September, $n = 34$; Fall: October–December, $n = 60$) and prevalence of *B. darlingi* cysts in opossums was recorded per season during the 1 year of study. Prevalence of *B. darlingi* infection between seasons was compared using chi-square analysis. Frequency of *B. darlingi* cysts occurrence among the different body locations taken was determined and compared using the Fischer's exact test and alpha was set at $P < 0.05$.

3. Results and discussion

Gross examination revealed numerous white glistening cysts on the outer surface of visceral organs, stomach, tongue, diaphragm, ears, abdominal muscles, and conjunctiva of infected opossums. Examination of H&E-stained sections revealed cysts of *Besnoitia* spp. measuring 490–660 µm (560 ± 64.42). Histological findings were similar to previous reports (Smith and Frenkel, 1977; Jack et al., 1989) and the cysts were characteristic of *B. darlingi* (Fig. 1). The parasitic cyst consisted of a single severely enlarged host cell. Numerous closely-packed banana-shaped bradyzoites were contained within a parasitophorous vacuole which filled the entire cell cytoplasm. The cell cytoplasm was compressed into a thin rim in the periphery with occasional elongated host cell nuclei forming an inner membrane of the cyst. On the outside of the cyst, there was a thick condensed, hyalinized, and laminated layer of collagen fibers forming cyst capsule (Fig. 1). This capsule was not uniform in thickness and measured 5–20 µm. Some cysts particularly in the lungs were collapsed, mineralized and surrounded by a mild cellular reaction composed mainly of mononuclear leukocytes. *B. darlingi* cysts were differentiated from those of other cyst-forming parasites such as *Sarcocystis* spp., *Toxoplasma gondii*, and *Frenkelia* spp. based on their characteristic thick connective tissue capsule that surrounded the tissue cyst proper. Histopathological slides of *B. darlingi* cysts from liver and heart of opossums were deposited at the United States National Parasite Collection (USNPC), Beltsville, MD, USA.

Ultrastructural examination of *B. darlingi* tissue cysts and bradyzoites showed cysts similar to tissue cysts described for *B. darlingi* (Jack et al., 1989; Dubey et al., 2002). Bradyzoites were crescent-shaped and had ultrastructural features identical to that of other Apicomplexa.

Overall prevalence of *B. darlingi* cysts in opossums (*D. virginiana*) found in this study was 10.9% (15/137) which is lower than that reported previously (Stabler and Welch, 1961; Conti-Diaz et al., 1970; Flatt et al., 1971; Smith and Frenkel, 1977; Jack et al., 1989), although the sample size of this study was much larger. Variations in prevalence of *B. darlingi* were detected between spring 17.6% (3/17), summer 29.4% (10/34), and fall

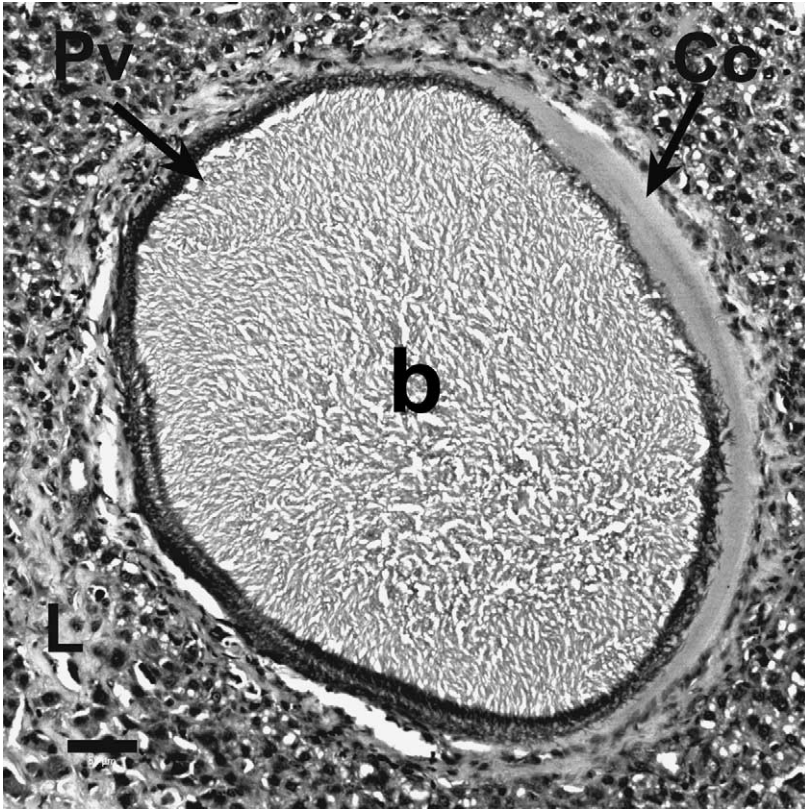


Fig. 1. Differential interference contrast (DIC) photomicrograph of a *B. darlingi* cyst in lung tissue (L) of a naturally infected opossum (*Didelphis virginiana*) showing the thick cyst capsule (Cc) enclosing the parasitophorous vacuole (Pv) that contains numerous crescent-shaped *B. darlingi* bradyzoites (b). HE, bar = 50 μ m.

3.3% (2/60), whereas no cysts were found in animals examined during winter 0% (0/26) (Table 1).

The fluctuation in *B. darlingi* prevalence with seasons could be explained by the hypothesis that prevalence is affected by climatic conditions and geographic locations. The lower exposure of opossums to *B. darlingi* oocysts in the fall and winter might explain the lower incidence of *B. darlingi* infection in Michigan opossums particularly at that time of the year. Assuming that *B. darlingi* infection has a short incubation period in the intermediate host as has been indicated in previous experimental studies, this data suggested that there is greater exposure to *B. darlingi* oocysts during warm weather. Also, opossums are more stressed during the breeding season in spring and summer. Moreover, the high prevalence during summer is expected because opossums are more active in home ranges during summer months (Gardner, 1982).

All 15 infected opossums with cysts were examined to determine which tissue was most likely to contain *Besnoitia* cysts. Generally, *B. darlingi* cysts may be found in many opossum tissues. However, Smith and Frenkel (1977) recorded the highest concentration of *B.*

Table 1

Prevalence of *B. darlingi* cysts in opossums of different ages and sex groups from Michigan by the different seasons during the year of study

Category	Spring	Summer	Fall	Winter	Total
Male	7	9	28	9	53 ^a
Adult	1/5	0/7	0/16	0/6	1/34 ^b
Juvenile	0/2	0/2	0/12	0/3	0/19 ^b
Female	10	25	32	17	84 ^a
Adult	2/8	10/13	2/24	0/15	14/60 ^b
Juvenile	0/2	0/12	0/8	0/2	0/24 ^b
Total ^c	3/17 (17.6)	10/34 (29.4)	2/60 (3.3)	0/26 (0)	15/137 (10.9)

^a Total number of opossums.

^b Number of positive per total examined.

^c Number of positive per total examined (%) per season.

darlingi cysts in the adrenal glands of opossums. They attributed this distribution to the immunosuppressive effects of the higher concentration of cortisol secreted in the adrenals that delayed the development of local immunity and thus, permitted *B. darlingi* to proliferate for a longer time than in other tissues leading to a greater number of cysts in this organ.

Although overwhelming, disseminated besnoitiosis was sometimes observed in all body tissues, the predilection of this parasite for the ears was consistently noticed (unpublished observation). More than 11 cysts were seen frequently in a single opossum ear, while no or few cysts were seen in other tissues. Ears were associated with the highest frequency of cyst isolation 66.7% (10/15), which was statistically significant when compared with other body tissues ($P < 0.05$). These results are in agreement with findings reported by Fitch and Sandidge (1953) who observed prominent concentrations of *Besnoitia* cysts on the ears, lips, and penis of opossums. Conjunctiva and tongue were identified as the next most frequent sites for cyst isolation 26.7% (4/15). Liver, spleen, heart, and kidneys had a prevalence of 20% (3/15) and diaphragm, stomach, and lung had a prevalence of cysts of 13.3% (2/15). However, cysts were found in the abdominal muscles of only one animal 6.7% (1/15). No cysts were detected in the adrenal glands of any animals.

Chobotar et al. (1970) reported heavy *B. jellisoni* infections in naturally infected kangaroo rats (*Dipodomys ordii*) with large numbers of cysts that might be debilitating if not fatal. In our study, all *B. darlingi*-infected opossums appeared to be in a poor body condition, suggesting that besnoitiosis is probably a serious disease of opossums. The possible contribution of *Besnoitia* infection to morbidity and impact of *Besnoitia* infection in opossum populations remains to be studied.

Significant association between age, sex and the occurrence of besnoitiosis in opossums was observed (Table 1). From all examined carcasses of different ages and sexes, the 15 *Besnoitia*-infected animals were all adult; 14 of these were female (93.3%).

There are three likely routes of transmission of *B. darlingi* to opossums in this area. First, these animals are often cannibalistic and are well known carrion feeders (Reynolds, 1945; Sandidge, 1953). Hence, necrophagous habits and bradyzoite transmission to intermediate hosts may account for the occurrence of *B. darlingi* in opossums. To the best of our knowledge, there is no other reported animal species in the Great Lakes area known to be infected

with *B. darlingi*, the likelihood of this infection in opossum through this route might be minimal.

Secondly, based on the common insectivorous habit of opossums Reynolds (1945), Sandidge (1953) and (Smith and Frenkel, 1977), suggested that this habit may play a significant role in the transmission of *B. darlingi* oocysts. In fact, insect vectors have been readily shown to transmit *Sarcocystis* spp. and other coccidia (Smith and Frenkel, 1978). Generally, insects are less active and remain hidden during the cold climate in the Northern US. Therefore, their potential role in transmission of *B. darlingi* during cold weather is low which may explain the differences observed in the prevalence of *B. darlingi* between seasons. Lastly, opossums may also become infected with *B. darlingi* orally by ingesting food or water contaminated with oocysts excreted by cats (Smith and Frenkel, 1977).

This study addressed the season, body condition, age, and sex that can be possible risk factors for *B. darlingi* infection in opossum. These data may be epidemiologically important and should help in identifying the impact of *B. darlingi* infection on wildlife possibly serving as definitive host.

Acknowledgements

We thank Drs. Thomas S. Whittam, Harold C. Schott, and Jeffrey P. Massey for their guidance. This work was funded by Department of Large Animal Clinical Sciences, College of Veterinary Medicine, Michigan State University Fellowship 71-8758. The study was conducted in accordance to the regulations of Michigan State University, All University Committee on Animal Use and Care (AUCAUC) and United States Department of Agriculture's approved guidelines for Animal care.

References

- Chobotar, B., Anderson, L.C., Ernst, J.V., Hammond, D.M., 1970. Pathogenicity of *Besnoitia jellisoni* in naturally infected kangaroo rats (*Dipodomys ordii*) in northwestern Utah. *J. Parasitol.* 56, 192–193.
- Conti-Diaz, I.A., Turner, C., Tweeddale, D.T., Furcolow, M.L., 1970. Besnoitiasis in the opossum (*Didelphis marsupialis*). *J. Parasitol.* 56, 457–460.
- Dubey, J.P., Lindsay, D.S., Rosenthal, B.M., Sreekumar, C., Hill, D.E., Shen, S.K., Kwok, O.C.H., Rickard, L.G., Black, S.S., Rashmir-Raven, A., 2002. Establishment of *Besnoitia darlingi* from opossums (*Didelphis virginiana*) in experimental intermediate and definitive hosts, propagation in cell culture, and description of ultrastructural and genetic characteristics. *Int. J. Parasitol.* 32, 1053–1064.
- Fitch, H.S., Sandidge, L.L., 1953. Ecology of the opossum on a natural area in northeastern Kansas. *Univ. Kans. Publ. Mus. Nat. Hist.* 7, 305–338.
- Flatt, R.E., Nelson, L.R., Patton, N.M., 1971. *Besnoitia darlingi* in the opossum (*Didelphis marsupialis*). *Lab. Anim. Sci.* 21, 106–109.
- Gardner, A.L., 1982. Virginia opossum. In: *Wild Mammals of North America, Biology, Management, and Economics* (Eds.). Johns Hopkins University Press, Baltimore, MD, pp. 3–26.
- Jack, S.W., Van Alstine, W.G., Swackhamer, J., 1989. Besnoitiasis in Indiana opossums. *J. Vet. Diagn. Invest.* 1, 189–191.
- Reynolds, H.C., 1945. Some aspects of the life history and ecology of the opossum in central Missouri. *J. Mammal.* 26, 361–379.
- Sandidge, L.L., 1953. Food and dens of the opossum (*Didelphis virginiana*) in northeastern Kansas. *Trans. Kans. Acad. Sci.* 56, 97–106.

- Schneider, C.R., 1967. The distribution of lizard besnoitiosis in Panama, and its transfer to mice. *J. Protozool.* 14, 674–678.
- Smith, D.D., Frenkel, J.K., 1977. *Besnoitia darlingi* (Protozoa: Toxoplasmatinae): cyclic transmission by cats. *J. Parasitol.* 63, 1066–1071.
- Smith, D.D., Frenkel, J.K., 1978. Cockroaches as vectors of *Sarcocystis muris* and of other coccidia in the laboratory. *J. Parasitol.* 64, 315–319.
- Smith, D.D., Frenkel, J.K., 1984. *Besnoitia darlingi* (Apicomplexa, Sarcocystidae, Toxoplasmatinae): transmission between opossums and cats. *J. Protozool.* 31, 584–587.
- Stabler, R.M., Welch, D.K., 1961. *Besnoitia* from an opossum. *J. Parasitol.* 47, 576.